

EVERYTHING YOU ALWAYS WANTED TO KNOW ABOUT



# Patent Foramen Ovale

By **GEORGE IRVINE**  
and **DAVID DOOLETTE**

Commercial diving long ago discovered that there are certain preconditions that increase a divers risk of Decompression Illness (DCI). Identifying these preconditions can provide divers with the opportunity to optimize their decompression procedures and reduce accident rates. The British recreational diving community long ago discovered that rapid onset neurological DCI occurring in divers using computers who fulfilled all decompression obligations can be correlated with a condition known as Patent Foramen Ovale (PFO).

Simply put, a PFO, or cardiac shunt is nothing more than a physiologic defect that can allow a portion of the blood traveling through the heart to be shunted, or detoured, into the arterial circulation without having first passed through the lungs. In adults, blood entering the right atrium of the heart from the venous system, is pumped to the right ventricle, and is then pumped through the pulmonary arteries to the lungs capillary beds, where it is oxygenated before returning to the left atrium. The blood is then pumped into the left ventricle,

and from there is pumped through the arterial side of the circulatory system supplying all the body tissue. Patent Foramen Ovale, Latin for "open oval hole," starts out harmlessly enough in all human beings during the prenatal stage of development. Before birth, there is a flap between the right and left atria of the heart (see figure 1). The fetus receives oxygenated blood from the placenta via the umbilical cord, which empties into the venous circulation and is carried directly to the right heart. The foramen ovale between the right and left atria allows this oxygenated venous blood to pass directly into the arterial circulation where it is needed, bypassing the useless, fluid filled lungs. When the baby is born, the lungs fill with air, and the resulting drop in right heart blood pressure

below left heart pressure causes the flap to be pushed shut, and in time heals permanently closed. Or, at least it is supposed to (see figure 2). In an estimated thirty percent of the population, there is some degree of incomplete closure, or a "swinging-

door" effect of this flap (see figure 3). These heart defects can range in severity from those that allow a minor leakage of blood, only under conditions of increased right atrial pressure, to those that allow unhindered shunting of

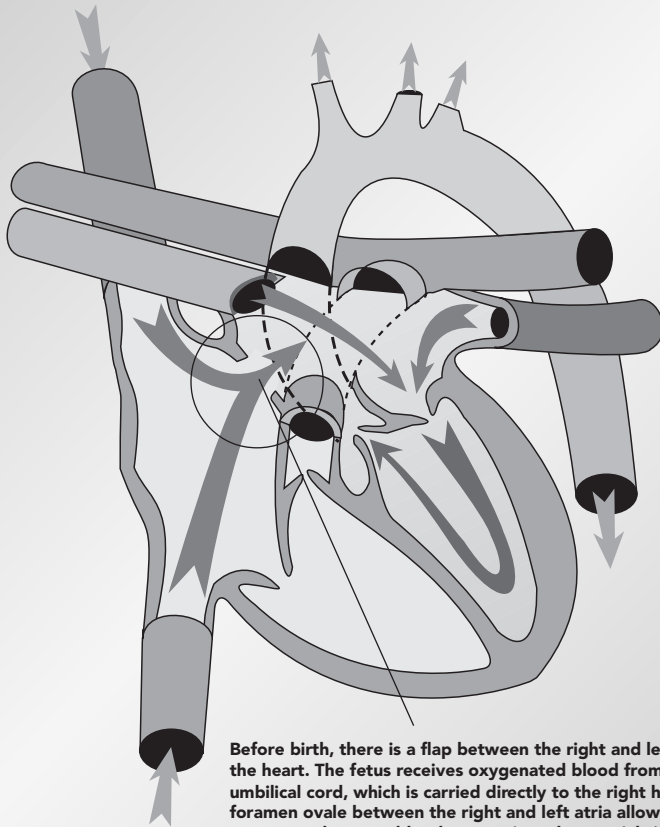
blood in ten to fifteen percent of the population.

The reason that a PFO is a problem in diving is that the lungs help protect us from decompression illness. Upon decompression, bubbles form in the venous circulation, and these bubbles †

**} Divers who have experienced rapid onset neurological DCI show a high incidence of PFO.~**

**continued next page †**

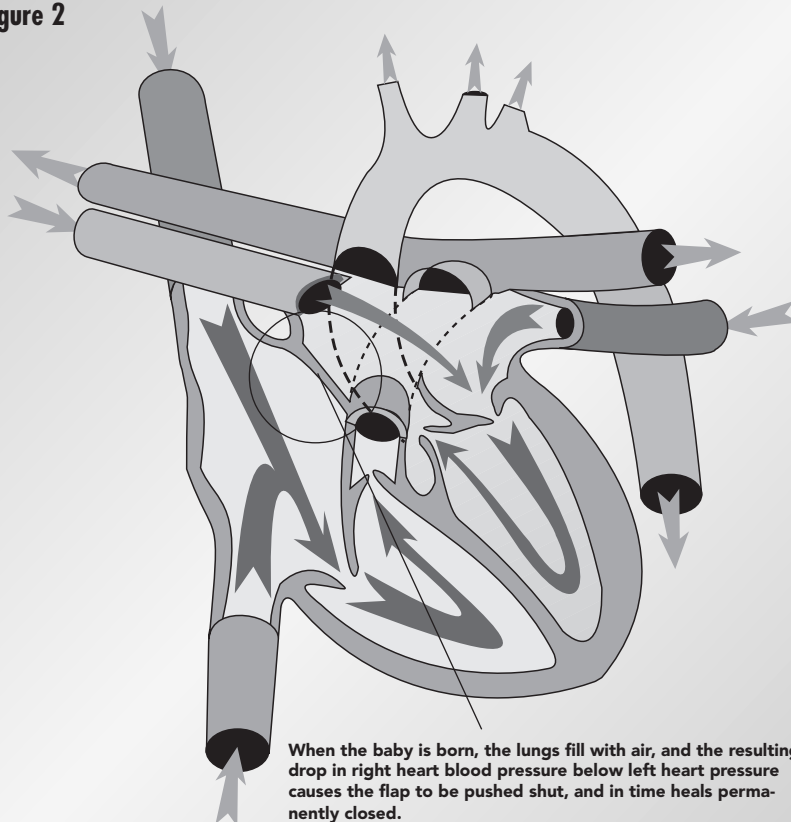
**Figure 1**



Before birth, there is a flap between the right and left atria of the heart. The fetus receives oxygenated blood from the umbilical cord, which is carried directly to the right heart. The foramen ovale between the right and left atria allows this oxygenated venous blood to pass into the arterial circulation, bypassing the fluid filled lungs.

Upright

**Figure 2**



When the baby is born, the lungs fill with air, and the resulting drop in right heart blood pressure below left heart pressure causes the flap to be pushed shut, and in time heals permanently closed.

Upright

are normally filtered out of the blood as it passes through the lungs. While the body can withstand a considerable load of venous bubbles (silent bubbles) without symptoms of decompression illness, even a small quantity of arterial gas bubbles can cause debilitating, or life threatening, decompression illness.

Venous blood, containing bubbles, can be shunted across the heart via a PFO into the arterial circulation. These bubbles will distribute according to buoyancy in the large arteries near the heart, and very likely ascend the carotid arteries toward the brain. Bubbles passing through the brain disrupt normal function and may even lodge temporarily in the smaller arterioles, blocking blood flow and having the same effect as a stroke. Any body function can be impaired by the ensuing brain damage, but frequently affected are: urinary control, speech, and motor control. At worst, these bubbles can cause paralysis or death. This condition has been termed "paradoxical gas embolism," so named because of its similarity to Cerebral Arterial Gas Embolism, one of the most dangerous forms of DCI, thought to occur as a result of breath-holding during ascent. Both these forms of DCI are characterized by neurological symptoms beginning either during ascent or within 30 minutes of surfacing. These conditions are often categorized under a dive industry euphemism called the "undeserved hit", because they can occur even if all decompression obligations are fulfilled.

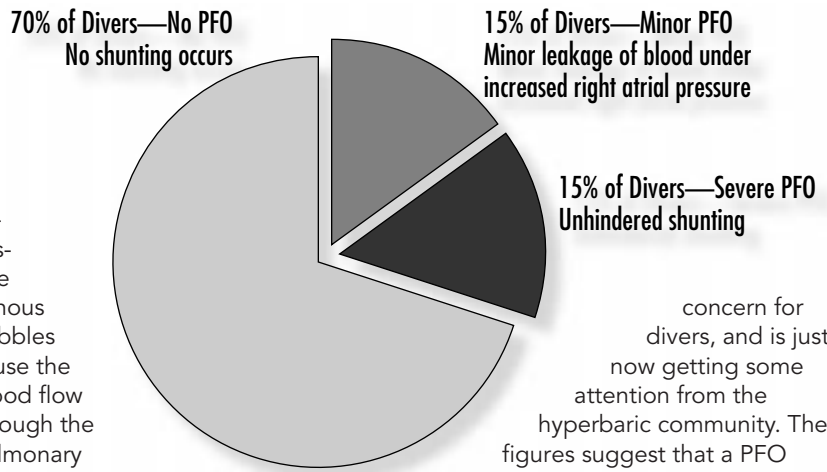
Divers who have experienced rapid onset neurological DCI show a high incidence of PFO that allow unhindered right-left blood shunting, so divers with this condition probably have a higher risk of paradoxical air embolism than the rest of the population. In addition to a PFO, a paradoxical air embolism requires venous bubbles, but these form after most dives. Since you are reading this in DeepTech, it is safe to say that you may at some time dive in a fashion that could lead to significant bubble formation, even if you don't typically build up large inert gas loads. For example: lets say you have been vacationing in the Solomon Islands for three days and are already residually loaded from your diving. Your regulator

fails while under a short decompression obligation on a 100 foot dive. You have to do an emergency swimming ascent and bubbles form in your blood from skipping your decompression stop. Combine this scenario with a PFO and you may get DCI and end up in a wheel chair.

Divers with PFO that only shunts blood with increased right atrial pressure are probably not at increased risk of paradoxical air embolism. However, many circumstances can lead to increased right atrial pressure, and promote right-left blood shunting, and this might put a diver with any type of PFO at risk. The Valsalva maneuver, for example, can temporarily increase right heart pressure, which might also occur as a result of urinating in your wetsuit, coughing, sneezing, climbing a boat ladder, or lifting tanks. Right atrial pressure will also increase when blood flow to the heart is increased by a well-meaning but ignorant divemaster putting you in the Van Trelenberg position on a dive boat to relieve the bends that he is helping to cause! Another way could be that

excessive venous bubbles cause the blood flow through the pulmonary capillary beds to become restricted, building back pressure on the right atrium.

A diver can dive uneventfully for years with PFO, and would never know the difference until that fateful day when a paradoxical air embolism occurs. Indeed, the statistics bear this out, since thirty percent of divers who have never had DCI have a PFO, just the same proportions as the rest of the population. Nevertheless, PFO is a

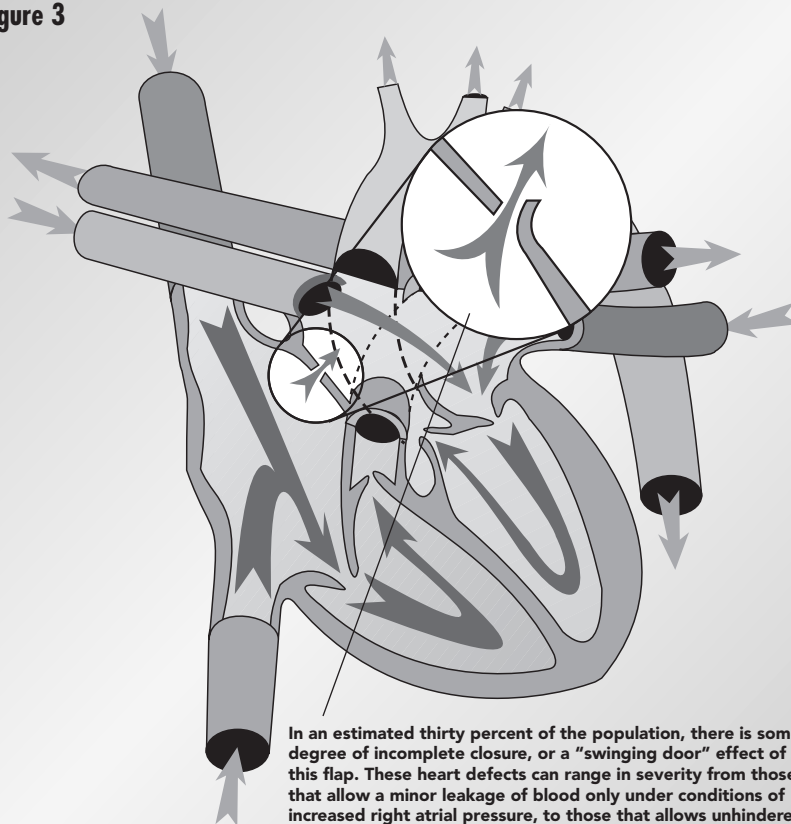


concern for divers, and is just now getting some attention from the hyperbaric community. The figures suggest that a PFO should not stop you from diving, but you might stop and think about the risk and modify your diving habits. If you want to do high exposure dives, or even if you just want to eliminate this one DCI risk factor - get tested for PFO. An echocardiogram with Doppler will show most PFO's. This is simply an ultrasound scan of the heart done by moving the instrument over the surface while watching a TV screen, which forms an amazing image of the heart, valves, and blood flow. Modern ultrasound equipment will make the heart look like you are holding it in your hand, and the test is less expensive than a dive computer. An extended test and monitoring period of 30-45 minutes is recommended with efforts designed to setup PFO shunting. Some doctors already have this equipment and can perform this test in their offices. If not, it is a simple matter to schedule the test in your local hospital.

George Irvine is a Stockbroker and Director of the Woodville Karst Plains Project (WKPP), and has many cave exploration accomplishments to his credit. Dr. David Doolette is in the Faculty of Medicine at The University of Adelaide, Australia, where he teaches physiology and pursues his research interests in diving and hyperbaric physiology. David has been diving for 16 years and is an active cave explorer.



**Figure 3**



In an estimated thirty percent of the population, there is some degree of incomplete closure, or a "swinging door" effect of this flap. These heart defects can range in severity from those that allow a minor leakage of blood only under conditions of increased right atrial pressure, to those that allows unhindered shunting of blood in ten to fifteen percent of the population.